

EKG

Name: **FABIO DELEK**

Sex: **Male** Age: **39**

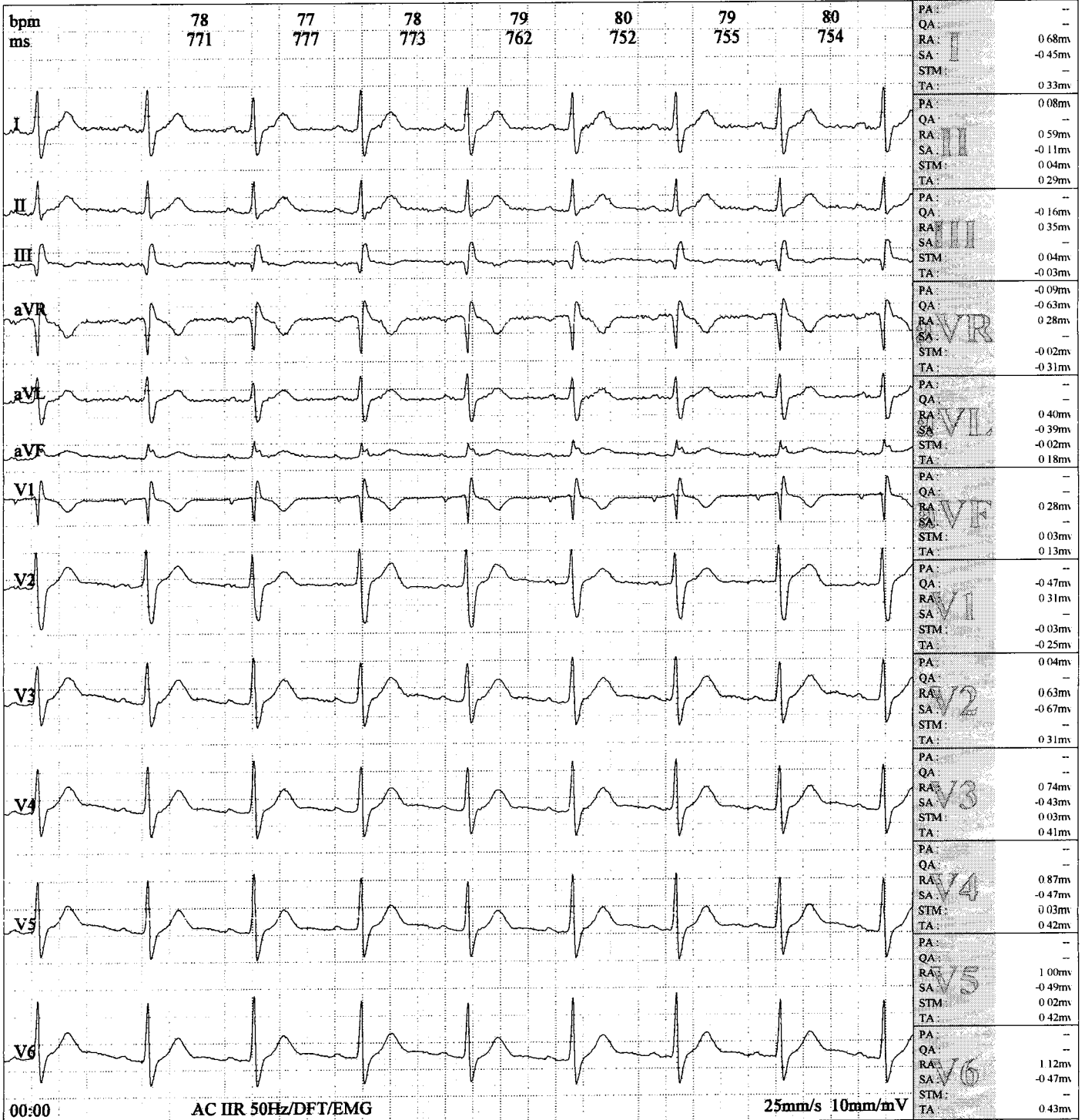
Clinic No.:

Section:

SN: **0019368** Case No.:

Bed No.:

Date: **10/06/2019**



| | | | |
|---------------|--------|---------------|--------|
| Frequency: | 1000Hz | PR Interval: | 249 ms |
| Sample Time: | 10s | QT Interval: | 377 ms |
| HR: | 79bpm | QTc Interval: | 431 ms |
| P Interval: | 165ms | P Axis: | 25.90° |
| QRS Interval: | 114 ms | QRS Axis: | 92.40° |
| T Interval: | 239 ms | T Axis: | 29.00° |

Prompt:
 Total Beats 12, Normal Beats 12, SVE 0, VE 0.
 Longitudinal Right axis deviation; I AV block; III Abnormal T wave;

*Ritmo sinusal, 79 bpm
 Sem alterações significativas.*

Physician Signature: